

ECHO ROUNDS Section Editor: Edmund Kenneth Kerut, M.D. _____

Posttraumatic Pulmonary Arteriovenous Fistula Presenting as Multiple Embolic Strokes

Theresa Mills, M.D.,* Shaminder Gupta, M.D.,† Frederick Helmcke, M.D.,* Jorge Lopera, M.D.,‡ Lynn Harrison, M.D.,§ Jorge Martinez M.D.,¶ David Luke Glancy, M.D.,* and Edmund Kenneth Kerut, M.D.**

*Division of Cardiology, LSU Health Sciences Center, New Orleans, Louisiana, †Department of Medicine, LSU Health Sciences Center, New Orleans, Louisiana, ‡Department of Radiology, LSU Health Sciences Center, New Orleans, Louisiana, §Department of Surgery, LSU Health Sciences Center, New Orleans, Louisiana, ¶Department of Emergency Medicine, LSU Health Sciences Center, New Orleans, Louisiana, **Departments of Physiology and Pharmacology, LSU Health Sciences Center, New Orleans, Louisiana, and Heart Clinic of Louisiana, Marrero, Louisiana

(*ECHOCARDIOGRAPHY, Volume 24, January 2007*)

pulmonary AV fistula, echocardiography, computed tomography, paradoxical embolism, stroke

A 52-year-old female presented with an acute embolic neurologic event manifested as sudden slurred speech, facial weakness, and an expressive dysphasia. These improved within 4 hours

of onset. Magnetic resonance imaging of the brain revealed several old strokes. Review of systems was pertinent for chronic exertional dyspnea. Past history was significant for a

Address for correspondence and reprint requests: Edmund Kenneth Kerut, M.D., Heart Clinic of Louisiana, 1111 Medical Center Blvd Suite N613, Marrero, Louisiana 70072. Fax: 504-349-6621; E-mail: kenkerut@pol.net

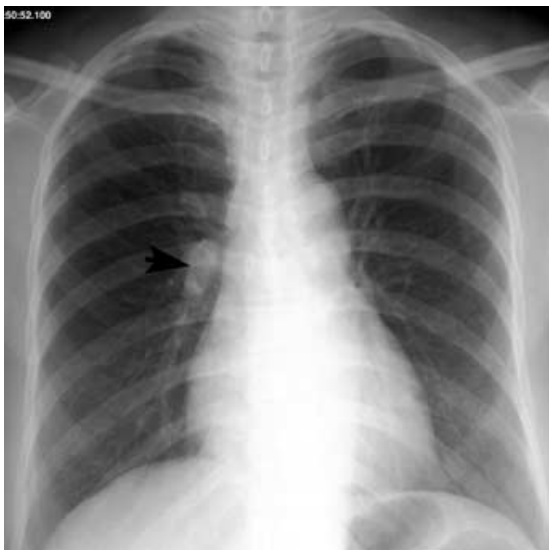


Figure 1. PA chest x-ray reveals a right hilar mass (arrow).

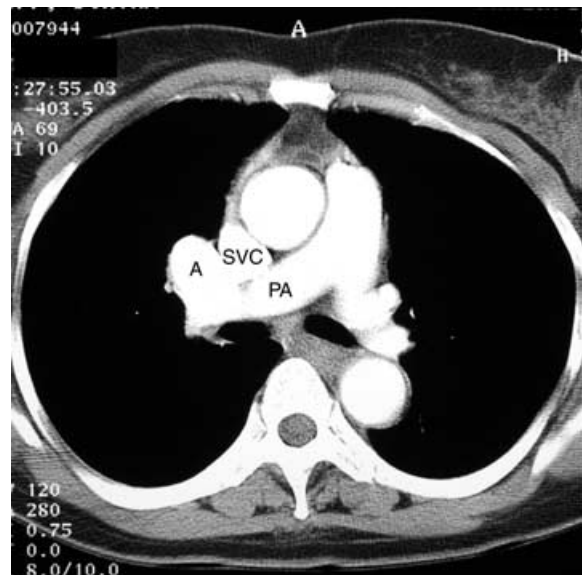


Figure 2. Cross-sectional computed tomography (CT) with intravenous contrast, at the level of bifurcation of the pulmonary artery. The right hilar mass noted by chest x-ray was found to be a vascular structure arising from the right pulmonary artery (PA). A = right hilar mass; SVC = superior vena cava.

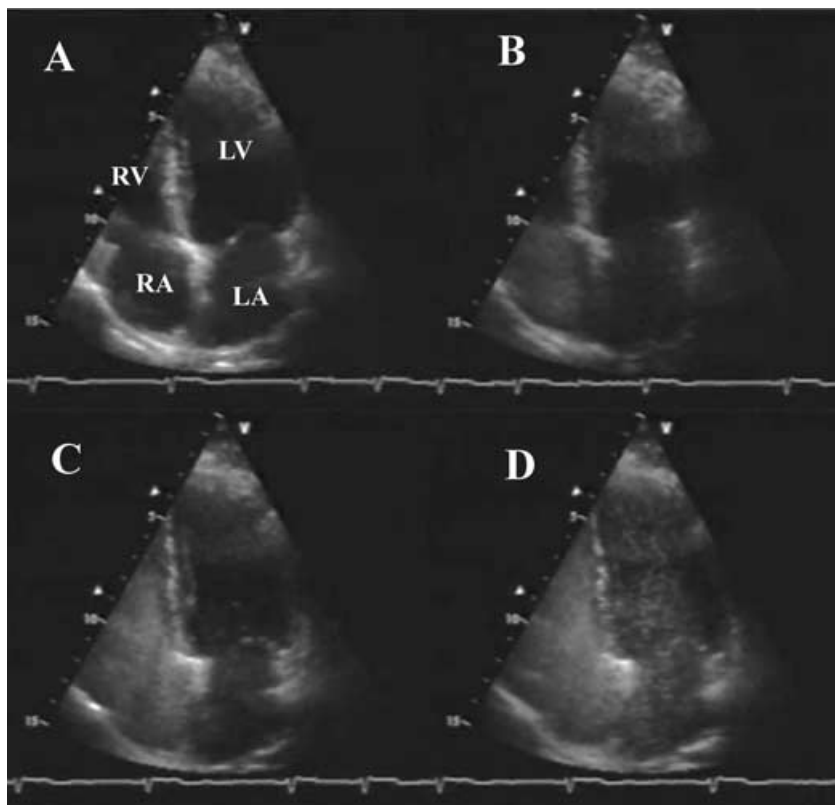


Figure 3. Sequential images from an apical four-chamber view during injection of agitated saline via the right antecubital vein (A–D). Contrast is initially noted to opacify the right atrium (RA) and right ventricle (RV). Within 2 cardiac cycles, contrast is noted to enter the left atrium (LA) and left ventricle (LV). VIDEO: Agitated saline injection via the right antecubital vein during normal respirations. Contrast is seen to fill the right heart. Two cardiac cycles later contrast also fills the left heart.

sudden right hemiparesis 15 years prior. In addition, the patient had a knife stab wound to the right chest requiring tube thoracostomy 20 years prior to admit.

A chest x-ray revealed a right hilar mass (Fig. 1). This appeared to be a vascular structure by computed tomography (CT) (Fig. 2). A transthoracic echocardiogram (TTE) revealed normal cardiac dimensions with normal pulmonary artery pressures and normal left ventricular (LV) systolic function. Through a right antecubital vein intravenous line, agitated saline was injected during normal respirations. Contrast filled the right heart and subsequently the left heart 2 cardiac cycles after its initial appearance within the right heart (Fig. 3).

Transesophageal echocardiography (TEE) was then performed. The right upper pulmonary vein (RUPV) subjectively appeared large. With antecubital vein saline contrast injection, microbubbles were noted to enter the LA via the RUPV (Fig. 4).

Based on these findings, a pulmonary arteriogram was performed (Fig. 5). This documented an arteriovenous (AV) fistula from the right pulmonary artery to the RUPV. Lower extremity venous duplex ultrasound did not yield any evidence of occult venous thrombosis.

The AV fistula was surgically repaired. A 1-cm diameter AV fistula was found extending from the right pulmonary artery to the RUPV. The patient had an uneventful recovery and was discharged home on the eighth day after admission. Her exertional dyspnea symptoms resolved postoperatively.

Most pulmonary AV fistulas are congenital, with up to 60% of those associated with hereditary hemorrhagic telangiectasia.^{1,2} Despite a relatively common occurrence of penetrating lung injury, traumatic pulmonary AV fistula is a seldom recognized finding.^{3–5} Although usually found soon after trauma,⁴ an occasional case has been noted as long as 10 years after a knife or gunshot wound.³ Our patient's AV fistula

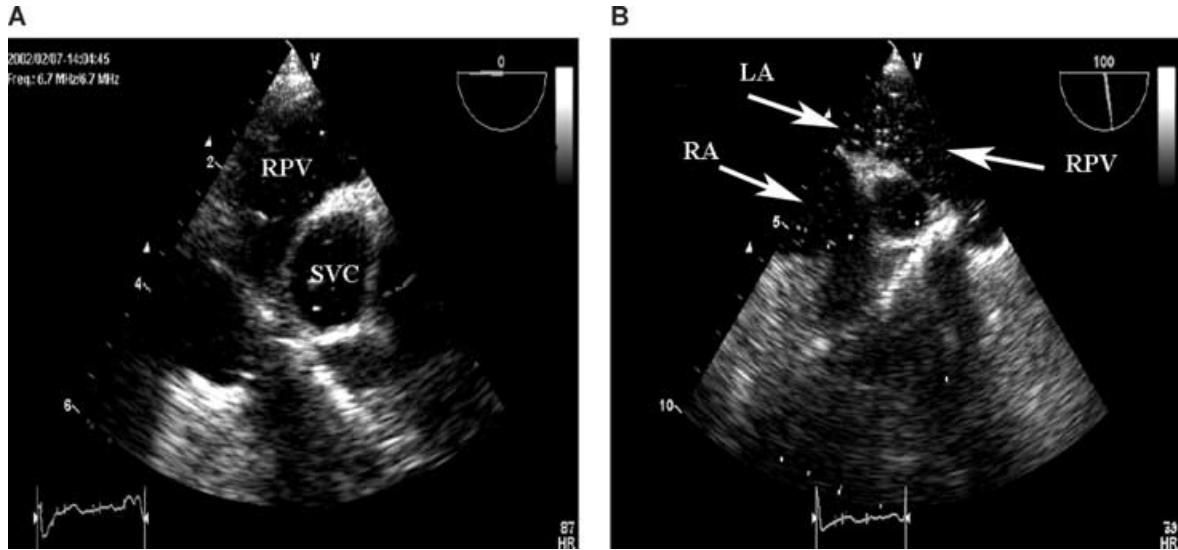


Figure 4. TEE in the upper esophagus in the (A) horizontal plane and (B) vertical plane (100°). Agitated saline contrast was noted to enter the left atrium (LA) via the right upper pulmonary vein (RPV). RA = right atrium; SVC = superior vena cava. VIDEO = TEE in the upper esophagus in the (A) horizontal plane and (B) vertical plane (100°). Saline contrast was noted to flow through an enlarged right upper pulmonary vein.

was not found for 20 years. Although presenting with a stroke 5 years after her lung injury (15 years prior to admission), the patient did not seek medical attention until presenting with a new neurologic event. It is likely that the source of her neurological events was paradoxical embolism through the identified pulmonary AV fistula.

Pulmonary AV fistula, as a form of right-to-left shunting can be readily diagnosed by peripheral venous saline contrast injection.⁶⁻⁸ As agitated saline contrast contains relatively large bubbles (~ 20–25 μm diameter), most bubbles are filtered out by the pulmonary bed. If a pulmonary AV fistula is present, a number of bubbles will “short-circuit” the pulmonary

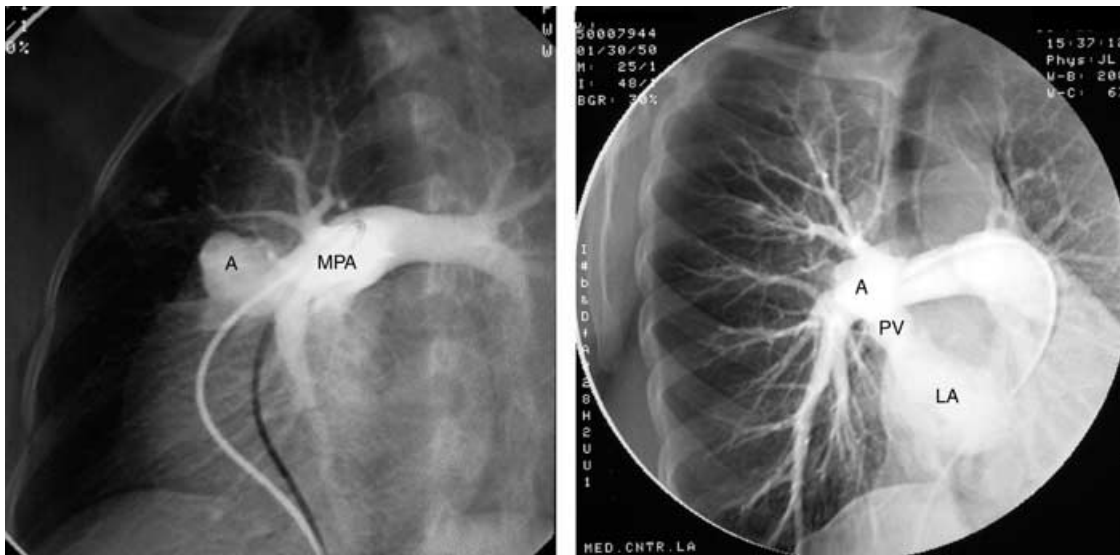


Figure 5. Pulmonary arteriography demonstrated a communication (A) between the right pulmonary artery and the right upper pulmonary vein (PV), draining into the right atrium (LA).

capillary system, and appear within the left heart.

For the diagnosis of a pulmonary AV fistula, it has been generally noted that from the appearance of contrast within the right heart, it takes greater than 3 cardiac cycles to appear within the left heart. In distinction to this, intracardiac right-to-left shunts (atrial level shunts) are usually noted to have contrast in the left heart within less than 3 cardiac cycles of its appearance within the right heart.^{9,10} This patient's contrast study was distinctly unusual, in that contrast filled the left heart within 2 cycles of its opacification of the right heart. In addition, as in this case, often the pulmonary vein receiving the shunted flow can be identified by noting saline contrast entering the left atrium through the involved pulmonary vein.^{11,12}

Several summarizing comments about pulmonary AV fistula include:

1. Pulmonary AV fistula may be the source of arterial embolic events.
2. Diagnosis can be made by echocardiography.
3. Usually saline contrast will opacify the left heart after 3 cardiac cycles of its appearance within the right heart. However, as noted in this case, contrast may appear earlier.
4. Often the involved pulmonary vein can be identified by TEE.

References

1. Dines DE, Arms RA, Bernatz PE, et al: Pulmonary arteriovenous fistulas. *Mayo Clin Proc* 1974;49:460-465.

2. Prager RL, Laws KH, Bender HW Jr: Arteriovenous fistula of the lung. *Ann Thorac Surg* 1983;36:231-239.
3. Arom KV, Lyons G: Traumatic pulmonary arteriovenous fistula. *J Thorac Cardiovasc Surg* 1975;70:918-920.
4. Symbas PN, Goldman M, Erbesfeld MH, et al: Pulmonary arteriovenous fistula, pulmonary artery aneurysm and other vascular changes of the lung from penetrating trauma. *Ann Surg* 1980;191:336-340.
5. Dairywala IT, Lokhandwala J, Patrick H, et al: Severe refractory hypoxemia following a gunshot injury. *Chest* 2005;127:398-401.
6. Seward JF, Tajik AJ, Hagler DJ, et al: Peripheral venous contrast echocardiography. *Am J Cardiol* 1977;39:202-212.
7. Hernandez A, Strauss AW, McKnight R, et al: Diagnosis of pulmonary AV fistula by contrast echocardiography. *J Pediatr* 1978;93:258-261.
8. Kerut EK, McIlwain EF, Plotnick G: *Handbook of Echo-Doppler Interpretation, 2nd Ed.* Armonk, NY, Blackwell-Futura Publishing Co., Inc, 2004, pp. 221.
9. Valdez-Cruz LM, Pieroni DR, Roland JM, et al: Echocardiographic detection of right-to-left shunts following peripheral vein injections. *Circulation* 1976;54:558-562.
10. Kerut EK, Norfleet WT, Plotnick GD, Giles TD: Patent foramen ovale: A review of associated conditions and the impact of physiological size. *J Am Coll Cardiol* 2001;38(3):613-623
11. Ammash NM, Seward JB, Warnes CA, et al: Partial anomalous pulmonary venous connection: Diagnosis by transesophageal echocardiography. *J Am Coll Cardiol* 1997;29:1351-1358.
12. Ahmed S, Nanda NC, Nekkanti R, et al: Transesophageal echocardiographic detection of a pulmonary arteriovenous malformation draining into left lower pulmonary vein. *Echocardiography* 2003;20(4):391-394

Supplementary Material

The following supplementary material is available for this article online: Movie clips: Figures 3, 4A, and 4B.