

## Structural Complications of Native Aortic Valve Endocarditis

Glenn P. Kelley, M.D.,\* Frederick R. Helmcke, M.D.,\* and Edmund Kenneth Kerut, M.D.\*†‡§

\*Department of Medicine, Section of Cardiology, Louisiana State University Health Sciences Center, New Orleans, Louisiana, †Heart Clinic of Louisiana, Marrero, Louisiana, ‡Cardiovascular Research Laboratory, LSU Health Sciences Center, New Orleans, Louisiana, §Division of Cardiology, Tulane University School of Medicine, New Orleans, Louisiana

(*ECHOCARDIOGRAPHY, Volume 21, May 2004*)

*aortic valve endocarditis, mitral valve aneurysm, mitral valve perforation*

A 39-year-old man presented with a 6-month history of exertional dyspnea and weight loss. There was no history of fever or recent dental work. Auscultation revealed a grade III diastolic, decrescendo murmur at the left upper sternal border and a grade III/VI holosystolic murmur at the cardiac apex. Blood cultures were all negative and the erythrocyte sedimentation rate was 3 mm/h.

Transthoracic (TTE) and transesophageal (TEE) echocardiography were performed using a VingMed 7 ultrasound system (GE VingMed Ultrasound, Horton, Norway). Mild left ventricular (LV) dilatation (LV end-diastolic dimension 58 mm, end-systolic dimension 40 mm) with an ejection fraction of 50% was noted. The left atrium (LA) was moderately enlarged (45 mm parasternal M-mode). Color Doppler findings (jet width > 50% aortic annulus dimension from a parasternal long-axis view), and continuous wave Doppler (pressure-half time 175 msec) were consistent with severe aortic regurgitation (AR). Pulsed wave Doppler from the suprasternal notch, just distal to the origin of the left subclavian artery, revealed pandiastolic reversal of flow. TEE imaging revealed a congenitally bicuspid aortic valve (AV) with anterior/posterior orientation of the cusps, and a 3-mm perforation of the posterior cusp, which was partially

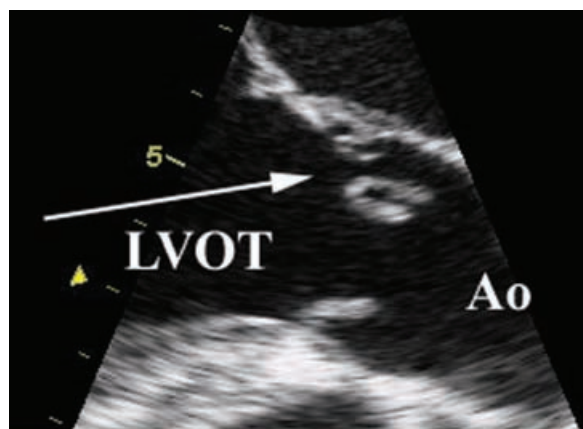
flail (Fig. 1). An echolucency in the mitral-aortic intervalvular fibrosa (MAIVF) was suggestive of a prior abscess in this structure. The anterior leaflet of the mitral valve (MV) had two large aneurysms (Fig. 2) with perforations resulting in several eccentric mitral regurgitant (MR) jets (Fig. 3). Diastolic MR flow was also observed (Fig. 4). No vegetation was visualized on either the mitral or AV leaflets. Right and left pulmonary vein flow patterns revealed a depressed systolic:diastolic flow ratio, and mitral inflow revealed predominantly early filling.

The aortic and mitral valves were replaced with mechanical prostheses. Echocardiographic findings of a bicuspid AV, posterior aortic flail leaflet with a perforation, MAIVF aneurysm, and anterior mitral leaflet aneurysm and perforation, were all documented by visual inspection at the time of surgery. Histopathologic analysis of the valve tissue revealed no evidence of active infection.

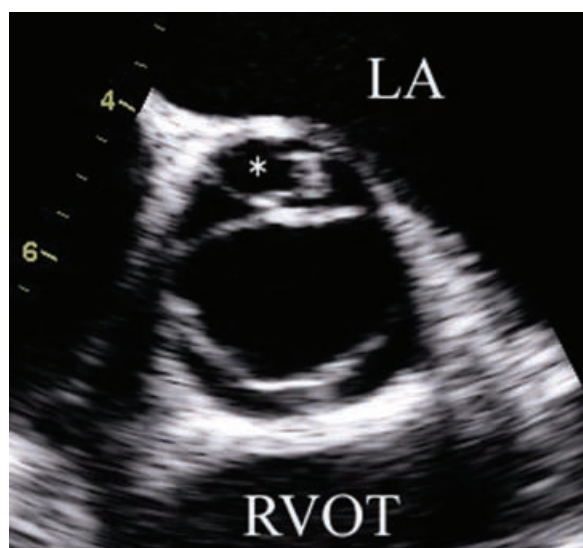### Discussion

Subaortic complications of native AV endocarditis are thought to result from direct extension of infection or from a regurgitant jet striking cardiac structures. Direct extension of infection to the aortic annular tissue results in abscess and, if the conduction system is involved, heart block. Regurgitant flow across infected AV tissue may strike the area of fibrous tissue linking the aortic annulus and the annulus of the anterior leaflet of the MV (MAIVF)

Address for correspondence and reprint requests: Glenn P. Kelley, M.D., LSU Health Sciences Center, Section of Cardiology, 2025 Gravier St. Suite 606, New Orleans, LA 70112. Fax: (504) 568-5845; E-mail: gkelle1@lsuhsc.edu



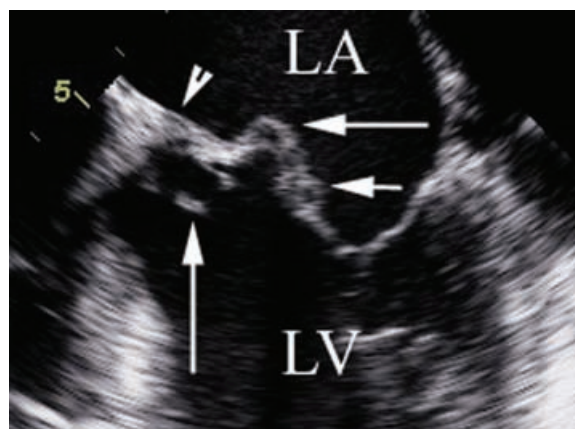A



B

**Figure 1.** Still figures from transesophageal echocardiogram. **A.** Longitudinal view from the level of the AV at end systole demonstrating perforation and partial flail of the posterior cusp into the aortic root (arrow). **B.** Transverse view of bicuspid AV from the upper esophagus at 37 degrees showing perforation of the posterior cusp (\*). Ao = proximal ascending aorta, LA = left atrium, LVOT = left ventricular outflow tract, RVOT = right ventricular outflow tract.

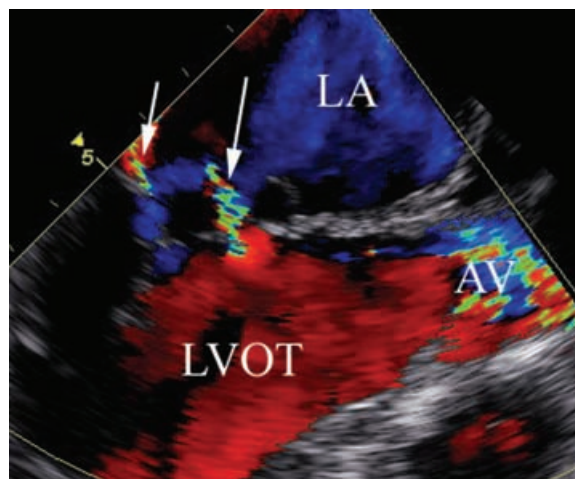
resulting in abscess or pseudoaneurysm. An MAIVF pseudoaneurysm may rupture to form a fistula between the left ventricular outflow tract (LVOT) and the LA, aorta, or pericardium. Similarly, AV regurgitant flow may strike the ventricular surface of the anterior leaflet of the MV, with subsequent “seeding” of infection and mitral aneurysm formation. Perforation of the anterior leaflet producing significant mitral regur-



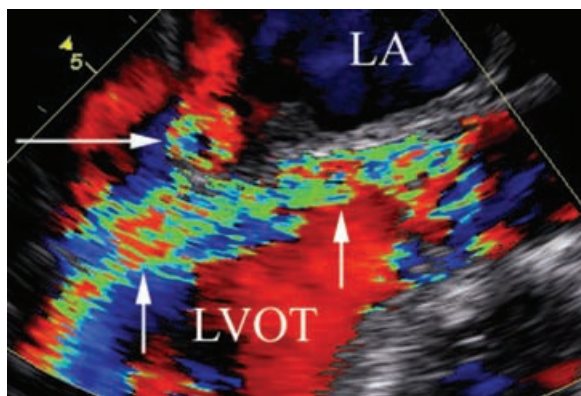
**Figure 2.** Diastolic 4-chamber view in horizontal plane in mid-esophagus showing multiple aneurysms of the anterior mitral leaflet (horizontal arrows). Note the proximity of the perforated, flail aortic cusp (vertical arrow) to the MAIVF (arrowhead), and the anterior mitral leaflet. LA = left atrium, LV = left ventricle.

gitation may occur with or without antecedent aneurysm (Fig. 5).

Abscess or pseudoaneurysm of the MAIVF is best visualized by TEE in a longitudinal long-axis view. It appears as an echo-free space in the intervalvular region.<sup>1</sup> Color Doppler of the space may show a brief burst of aliased flow in early systole and early diastole as blood flows in and out of the pocket. Fistula formation between the LVOT and the LA



**Figure 3.** TEE systolic frame at 110 degrees showing two eccentric, regurgitant jets directed toward the lateral wall of the LA (arrows). Note the color turbulence through the bicuspid AV. AV = aortic valve, LA = left atrium, LVOT = left ventricular outflow tract.



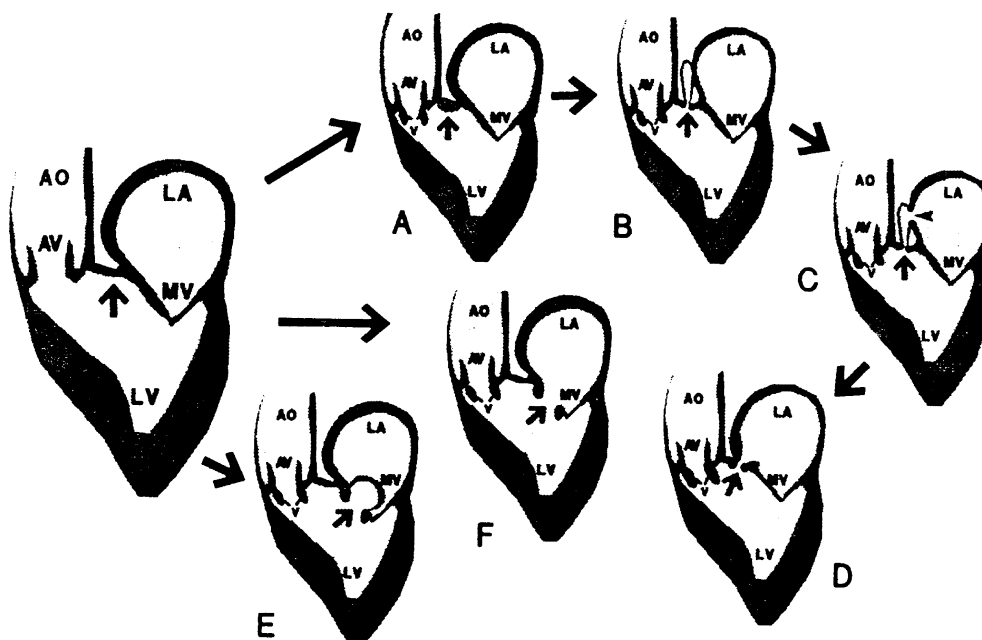
**Figure 4.** End-diastolic frame from the long axis at 110 degrees with color Doppler. Note diastolic mitral regurgitation (horizontal arrow). Early filling of the left ventricle from the aortic regurgitant volume (vertical arrows) results in diastolic mitral regurgitation. LA = left atrium, LVOT = left ventricular outflow tract.

can be difficult to distinguish from MR by TTE, though an eccentric color jet directed toward the lateral wall of the LA suggests this abnormality.<sup>2,3</sup>

Recognition of subaortic complications of AV endocarditis prior to surgical intervention is an important goal. Foremost, AV endocarditis frequently results in hemodynamically significant AR and the presentation of the additional hemodynamic burden from mitral regurgitation or intracardiac shunting may result in further complications. Furthermore, the surgical approach to AV replacement often does not allow adequate visualization of subaortic structures.

Prior to use of TEE, subaortic complications of AV endocarditis were believed to occur infrequently. Karalis et al. found evidence of subaortic involvement using TEE in 24 (44%) out of 55 consecutive cases of native and prosthetic AV endocarditis.<sup>2</sup> Sensitivity of TTE for identifying subaortic AV endocarditis complications is 20%–40%, while the sensitivity of TEE approaches 100%.<sup>2–4</sup> Therefore, TEE is indicated for both native and prosthetic AV endocarditis.

In summary, structural complications of AV endocarditis (native and prosthetic) appear to be a relatively common finding. Involvement of the MAIVF and the MV are discussed and



**Figure 5.** Schematic of the long-axis view of the heart and subaortic structures in AV endocarditis. Panels A through D represent complications of secondary infection of the MAIVF (arrow). Panel A shows MAIVF abscess, panel B shows aneurysm, panel C shows rupture of the aneurysm into the LA (arrowhead), and panel D shows rupture of the MAIVF into the LA without formation of an aneurysm. Panels E and F show complications resulting from secondary infection of the anterior mitral leaflet. Panel E demonstrates formation of an aneurysm, and panel F shows perforation of the anterior mitral leaflet. AO = aorta, AV = aortic valve, LA = left atrium, LV = left ventricle, MV = mitral valve, V = vegetation. (Reprinted with permission from Ref. 2).

illustrated. TEE is an excellent method for the characterization of these structural complications.

### References

1. Khandheria B, Freeman W, Sinak L: Infective endocarditis evaluation by transesophageal echocardiography. In Freeman W, Seward J, Khandheria B, et al (eds): *Transesophageal Echocardiography*. Boston, MA, Little, Brown and Co., 1994, p. 317.
2. Karalis D, Bansal R, Hauck A, et al: Transesophageal echocardiographic recognition of subaortic complications in aortic valve endocarditis. *Circulation* 1992;86:353-362.
3. Afridi I, Apostolidou M, Saad R, et al: Pseudoaneurysms of the mitral-aortic intervalvular fibrosa: Dynamic characterization using transesophageal echocardiographic and Doppler techniques. *J Am Coll Cardiol* 1995;25:137-145.
4. Bansal R, Graham B, Jutzy K, et al: Left ventricular outflow tract to left atrial communication secondary to rupture of the mitral-aortic intervalvular fibrosa in infective endocarditis: Diagnosis by transesophageal echocardiography and color flow imaging. *J Am Coll Cardiol* 1990;15:499-504.